

A TECHNIQUE FOR LID LOADING IN THE MANAGEMENT OF THE LAGOPHTHALMOS OF FACIAL PALSY

RICHARD P. JOBE, M.D.

Los Altos, Calif.

Weighting of the upper lid with gold, to provide closure and cosmetic improvement in a lagophthalmos due to facial palsy, has found increasing acceptance among plastic surgeons and ophthalmologists since it was described by Smellie⁹ in 1966. The technique we have developed after a 4-year experience with this procedure has proved to be good, and it can be easily modified as the clinical circumstances change. The availability of a standardized gold weight* will make it possible to extend the usefulness of the procedure.

Paralysis of the *orbicularis oculi* limits the ability of the lids to close. In younger patients, the elasticity of the skin assists in closure. The older the patient, the more lax the skin and the greater the need for therapy. The addition of a gold weight to the upper lid assists in replacing *orbicularis* function. We have found that variations in the weight and thickness of the eyelid tissues, and in the strength of the *levator palpebrae* muscle, cause considerable individual variation in the amount of gold necessary to achieve a satisfactory result.

EVALUATION OF THE PATIENT

Upper lid loading may be considered for any patient with symptoms that require such temporary measures as taping the upper lid down at night or using artificial tears, eye drops, or ointments to prevent corneal drying. The operation

* Heyer-Schulte Corp., 5377 Overpass Rd., Santa Barbara, Calif. 93111.

may be performed also for purely cosmetic reasons, as in all cases the cosmetic deformity is at least mildly annoying; in some cases it is agonizing.

The operation may not be suitable for all patients, even those with severe deformities. It is not as effective for corneal protection as an extensive tarsorrhaphy;⁵ even when the results are optimal, the patient must still be relied on to cooperate in the treatment and prevention of ocular irritation, conjunctivitis, corneal ulceration, *etc.* The lid loading operation should be reserved for the alert, cooperative patient who can be depended on to follow instructions for instillation of medications and for follow-up visits. One should be cautious in recommending it for patients with accompanying trigeminal nerve lesions and insensitive corneas.

THE PROSTHESIS

The prostheses used are finished 99.99 percent pure gold bars measuring (cross-section) 1 × 4.5 mm. The lengths used vary with the weight required (Fig. 1). They are available in kits containing 6 different weights: 0.6, 0.8, 1.0, 1.2, 1.4, and 1.6 gm. The weights are curved on a radius of 12.5 mm; each has a central drill hole for suture fixation.

Gold is the preferred material, because it is heavy (sp gr 19.21) and because its color is somewhat similar to that of fat. Silver-colored metals show through the skin of the lids as black.² Gold may show through in very thin lids, but is less noticeable.

From the Department of Surgery of the Stanford University School of Medicine, Stanford, Calif.
Presented, in part, at the Annual Meeting of the American Association of Plastic Surgeons on May 12, 1970 in Colorado Springs, Colo.

PREOPERATIVE FITTING

The weight of the prosthesis to be implanted is determined before operation by testing the lid with different weights. A small amount of rubber cement, dermatome glue, or tincture of benzoin is applied to the concave side of the one gm prosthesis. With the patient sitting upright (Fig. 2), the weight is affixed to the upper lid just above the lashes, centered at the junction of the medial and central thirds of the lid (the point at which leva-




FIG. 1. Solid gold lid loads in 6 sizes, from .6 to 1.6 gm (at .2 gm intervals). They are marked for weight and curved on a radius of 12.5 mm—approximately the usual curvature of the tarsal plate.

tor function is maximal). The effect as the patient looks up and down is noted, and the weight is changed until the best result is achieved. The desirable weight is usually that which holds the lid about one mm lower than the normal lid when the patient looks straight ahead. This is because the levator seems to strengthen after the weight is added.

When the prosthesis of the proper weight has been chosen, it should be cleaned with soap and water, rinsed thoroughly in distilled water, and autoclaved in preparation for use.

SURGICAL PROCEDURE

Local or general anesthesia may be used.

The incision is horizontal, 1.5 to 2.0 cm long, in the deep portion of the upper lid sulcus. The incision should be centered at the juncture of the medial and central thirds of the lid. It should be carried just through the *orbicularis* muscle fibers to the plane beneath the *orbicularis*.

By blunt dissection, the plane is opened to make room for the prosthesis on the surface of the orbital septum and the tarsal plate. The prosthesis will usually rest most comfortably with its lower edge a few millimeters above the lid margin. The prosthesis is tied to the orbital septum with a single 5-0 or 6-0 nonabsorbable suture, to hold it in place until the tissues heal around it.

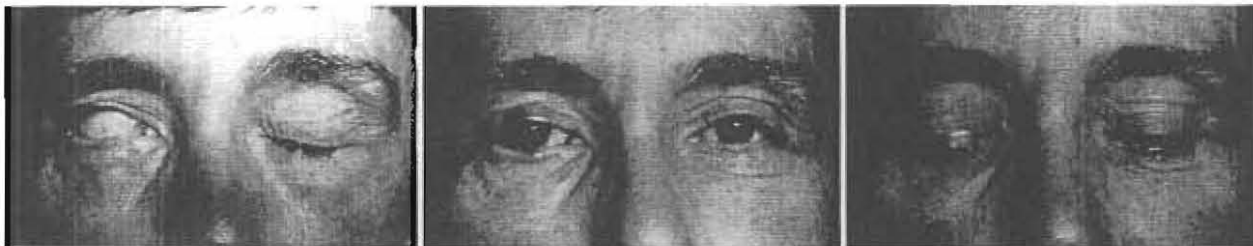

FIG. 2. Testing for the proper size of gold weight in a 47-year-old stenographer, 5 months following a resection of an eighth nerve tumor with destruction of her facial nerve. (left) Position of her lids during closure, one day following the division of a protective tarsorrhaphy. This demonstrates absence of *orbicularis* function. The extreme elevation of her upper lid probably results from adhesions between the superior rectus muscle and the levator, associated with Bell's phenomenon causing the superior rectus to rotate the globe upward on closure. (center, right) Functional alteration occurring with a 1.4 gm gold prosthesis glued to her eyelid (with dermatome glue), while she is looking forward and down.

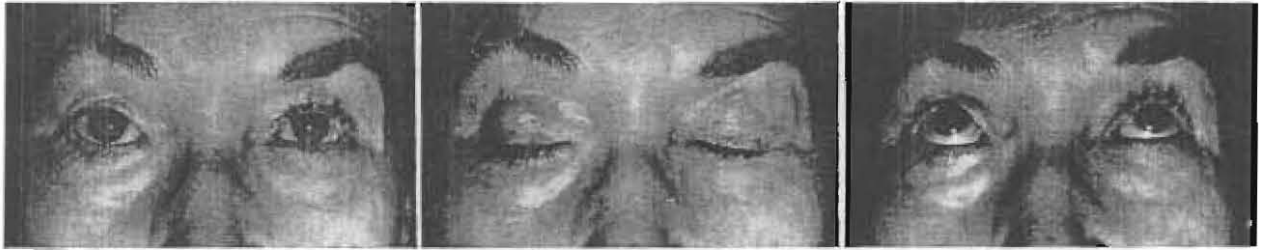

FIG. 3. A 65-year-old retired legal stenographer, one of our first patients, had 1.15 gm of gold in 3 blocks placed in her upper lid one week after an intracranial destruction of her seventh nerve. The initially placed gold blocks drifted about, became conspicuous, and were apparently less than the necessary weight for function. In November 1972, the original weights were removed and replaced by a 1.4 gm prosthesis, as described. The patient also had a medial canthoplasty, a lateral canthoplasty, and a lower lid fascial sling done a few months after her craniotomy. Shown here are the appearance and function of her lid two months after the second gold implant. The right brow is elevated slightly with tape, to improve your view of her upper lid.

The prosthesis is placed a short distance above the lid margin so that it will not be evident in the thinnest portion of the lid. A slight bulge from the prosthesis is visible on close inspection, but is not easily noticeable on casual observation.

The skin and *orbicularis* are closed by the method of the surgeon's choice. An eyepad dressing is applied until the patient is alert and has recovered completely from the anesthetic.

The levator strengthens slightly as the weight is worn. It is occasionally necessary to replace the prosthesis with a heavier one after a few months.

RESULTS AND COMMENTS

The gold weight does not interfere with elevation of the lid (Fig. 3), but allows the lid to fall when the levator relaxes—as in downward gaze, blinking, and lid closure. It does not compensate perfectly for *orbicularis* palsy, but it helps to protect the cornea, gives an appearance of normal movement to the lids and, in many instances, makes it possible to avoid more deforming operations.

Upper lid loading alone is of value in patients who are slowly recovering from Bell's palsy. The weight can easily be removed when it is no longer needed. In more permanent states, it can be used to complement other procedures—such as the McLaughlin lateral canthoplasty,⁵ a

brow lift, or lower lid shortening procedures for ectropion, lower lid supporting procedures, fascial slings, or a medial canthoplasty.

Lid loading by itself does not eliminate the necessity for nocturnal corneal protection with patches, cones, taping, eye drops, or ointments—whatever the patient and his doctor have found to be most effective. When eyelid loading is combined with other procedures, however, protection of the cornea at night may not be necessary. Elevation of the head at night is often helpful after lid loading.

The procedure does not modify the success of other procedures combined with it, but it does reduce the need for deforming tarsorrhaphies.

SUMMARY

A technique for placing gold weights in the upper lids to relieve lagophthalmos in patients with facial palsy is described. The indications and other applications of the technique are presented.

Richard P. Jobe, M.D.
762 Altos Oaks Drive
Los Altos, Calif. 94022

Dr. Jobe is Associate Clinical Professor of Surgery at Stanford University School of Medicine, Stanford, Calif.

REFERENCES

1. Barclay, T. L., and Roberts, A. C.: Restoration of movement to the upper eyelid in facial palsy. *Brit. J. Plast. Surg.*, 22: 257, 1969.
2. Cronin, T.: Cited in section on facial paralysis, by Freeman, B. S. In *Reconstructive Plastic Surgery*, Vol. 3, edited by J. M. Converse. W. B. Saunders Co., Philadelphia, 1964.
3. Guy, C. L.: The palpebral spring for paralysis of the upper eyelid in facial nerve paralysis. Presented at the 38th Annual Meeting of the American Society of Plastic and Reconstructive Surgeons in St. Louis, October 1969.
4. Illig, K. M.: Eine neue Operationsmethode gegen Lagophthalmos. *Klin. Monatsbl. Augenheilkd.*, 132: 410, 1958.
5. McLaughlin, C. R.: Epiphora in facial paralysis. *Brit. J. Plast. Surg.*, 3: 387, 1950.
6. Marino, H.: Dynamic, static and complementary procedures in the treatment of paralysis of the orbicularis oculae. In *Proceedings of the Second International Symposium on Plastic and Reconstructive Surgery*. C. V. Mosby Co., St. Louis, 1967.
7. Morel-Fatio, D., and Lalardrie, J. P.: Palliative surgical treatment of facial paralysis. *Plast. & Reconstr. Surg.*, 33: 446, 1964.
8. Sheehan, J. E.: Progress in correction of facial paralysis with tantalum wire and mesh. *Surgery*, 27: 122, 1950.
9. Smellie, G. D.: Restoration of the blinking reflex in facial palsy by a simple lid-load operation. *Brit. J. Plast. Surg.*, 19: 279, 1966.